Accuracy of Bone-Mounted Miniature Robotic Guidance System for Pedicle and Translaminar Facet Screw Placement

Daisuke Togawa, MD, PhD*, Mark M. Kayanja, MD, PhD*, Isador H. Lieberman, MD, MBA, FRCS(C)*, Edward C. Benzel. MD*
Mary Kay Reinhardt, RN*, Nachshon Knoller, MD**, Alon Friedlander, MD**

*Spine Institute, The Cleveland Clinic Foundation, Cleveland, Ohio, USA. ** Department of Neurosurgery, Sheba Medical Center,Ramat Gan, Israel.

Background

Spinal instrumentation involving pedicle screws, facet screws or translaminar facet screws is well established and frequently used to help achieve spinal fusion. However, these techniques usually require an extensive exposure to identify the insertion point and appropriate trajectory. A miniature bone-mounted guiding robot and accompanying proprietary software (SpineAssist, MAZOR Surgical Technologies, Ltd., Caesarea, Israel) was developed and tested. The software features automatic CT-to-fluoro image registration together with pre-operative planning. It is relatively easy to use and is simple and user-friendly. The miniature robot guides the surgeon to the desired entry point and trajectory according to the pre-operative plan.

Purpose

The purpose of this study was to evaluate the accuracy of this novel bone-mounted miniature robotic system for percutaneous placement of pedicle and translaminar facet screws.

Methods

Thirty-six spinal levels in ten cadavers were instrumented. Each cadaver's entire spine was pre-procedurally scanned. Surgeons planned optimal entry points and trajectories for screws on reconstructed three-dimensional virtual X-rays of each vertebra. Either a clamp or a minimally-invasive frame was attached to the bony anatomy. AP and lateral fluoroscopic images utilizing targeting devices were synchronously registered with the virtual X-rays of each vertebra generated from the pre-procedural CT scan. The miniature robot was mounted onto the clamp/frame and the system controlled the robot's motions to align the drill guide along the pre-planned trajectory. K-wires were introduced through the drill guide and left inside the cadaver. Cadavers were post-procedurally CT-scanned and the system's accuracy was evaluated in three planes, comparing wire positions to the pre-operative plan. A total of fifty-five procedures were evaluated.



(A) (B)

Figure 1 SpineAssist system
(A) Bone-mounted miniature robot (B) Work station.
(MAZOR Surgical Technologies Ltd., Caesarea, Israel).

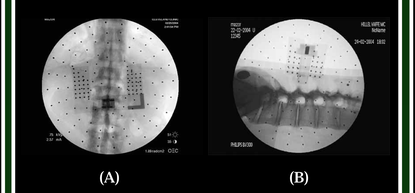

(A) (B)

Figure 2 Fluoroscopic images with target
(A) Anterior-posterior view,
(B) Lateral view

Figure 3 Image Registration

(A) (B)

Figure 4 Surgical Planning
(A) pedicle screw application
(B) Translaminar facet screw application
Different size and diameter screws are available in the planning section.

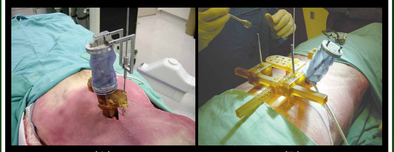

(A) (B)

Figure 5 Device Positioning
(A) pedicle screw application
(B) Translaminar facet screw application.

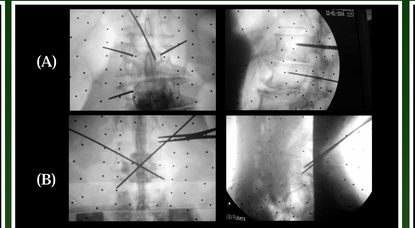

(A)
(B)

Figure 6 Radiographic Studies
(A) pedicle screw application
(B) Translaminar facet screw application

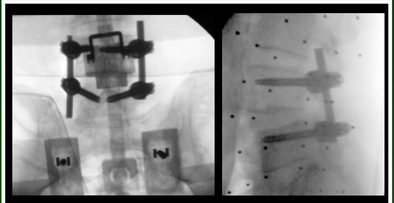

AP view Lateral view

Figure 7 Post-procedural X-rays of cadaveric spine using SpineAssist combined with Pathfinder (Abbott Spine™)

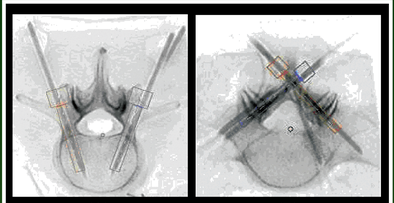

(A) (B)

Figure 8 Accuracy Evaluation
(A) pedicle screw application
(B) Translaminar facet screw application

Results

Pedicle Screw Application: Twenty-nine of Thirty-two K-wires and all four screws were placed with less than 1.5 mm deviation; average deviation was 0.87+/-0.63 mm (0-1.7 mm) from preoperative plan in this group.

Translaminar Facet Application: Sixteen of nineteen K-wires were placed with less than 1.5 mm deviation. There were one-broken and one-bent K-wire. Another K-wire was misplaced because of collision with the previously placed wire on the contralateral side of the same vertebra due to a mistake in planning, resulting in 6.5 mm deviation. When this case was excluded, average deviation was 0.82+/-0.65 mm (0-1.5 mm).

Conclusions

We present an accuracy evaluation of percutaneous pedicle screw and translaminar facet screw placement using a miniature robot directly mounted on the patient's spine. Registration of pre-procedural CT with intra-operative fluoroscopic images was validated. These results verify the system's accuracy and support its use in minimally invasive surgery in selected cases. With continuous efforts focusing on system and instrument improvements, such technology may find a firm niche in the armamentarium of the minimally invasive spine surgeon.